

# High-Grade Gliomas in Children

Tene A. Cage, MD<sup>a,\*</sup>, Sabine Mueller, MD, PhD<sup>b,c</sup>,  
Daphne Haas-Kogan, MD<sup>c,d</sup>, Nalin Gupta, MD, PhD<sup>a,c</sup>

## KEYWORDS

- Glioblastoma multiforme • Anaplastic astrocytoma • Pediatric brain tumors • Radiation therapy
- Chemotherapy

## KEY POINTS

- High-grade gliomas include anaplastic astrocytomas and glioblastomas. They account for 3% to 7% of primary brain tumors in children and peak in incidence during adolescence.
- Molecular mutations seen in pediatric glioblastoma multiforme and AAs include p53, PTEN, and LOH at 10q23. p53 and PTEN are associated with a poor prognosis.
- The goals of surgery include pathologic diagnosis and/or gross total resection. Longer progression-free survival is associated with a greater extent of resection.
- In children older than 3 years, chemotherapy plus radiation after surgery is the standard of care. In children younger than 3 years, radiation is associated with significant neurologic morbidity and should be used only when necessary.

## INTRODUCTION

Gliomas are primary brain tumors derived from astrocytes and oligodendroglia and are historically separated into low- or high-grade categories according to the World Health Organization (WHO) classification system. Low-grade astrocytomas (WHO grade I and II) are approximately 40% of primary supratentorial tumors of childhood and are more common than high-grade astrocytomas (WHO grade III and IV).<sup>1</sup> Supratentorial high-grade gliomas (HGGs) are further divided into anaplastic astrocytomas (AAs, WHO grade III), anaplastic oligodendrogliomas (WHO grade III), mixed astrocytic tumors, and glioblastoma multiforme (GBM, WHO grade IV).<sup>2</sup> As expected, survival rates are poor and mortality is highest in patients with malignant astrocytomas.

## EPIDEMIOLOGY

HGGs account for between 3% and 7% of newly diagnosed primary brain tumors in children.<sup>3,4</sup> GBM is the most common primary brain tumor in the adult population, but GBMs along with AAs account for only about 20% of pediatric supratentorial brain tumors.<sup>1</sup> In the pediatric population, malignant astrocytomas seem to affect boys and girls equally.<sup>5</sup> The incidence peaks during adolescence, although very young children can also develop malignant astrocytomas.<sup>5</sup>

At present, the only known risk factor associated with developing an HGG is prior radiation therapy.<sup>6</sup> Other rare risk factors include genetic syndromes such as Li-Fraumeni syndrome. This syndrome is characterized by 1 or more cancer occurrences in children, including HGGs.<sup>7,8</sup> Mutations of the p53

<sup>a</sup> Department of Neurological Surgery, University of California, San Francisco, 505 Parnassus Avenue, Room M779, San Francisco, CA 94143-0112, USA; <sup>b</sup> Department of Neurology, University of California, San Francisco, 505 Parnassus Avenue, Box 0114, San Francisco, CA 94143-0114, USA; <sup>c</sup> Department of Pediatrics, University of California, San Francisco, 505 Parnassus Avenue, M696, Box 0110, San Francisco, CA 94143, USA; <sup>d</sup> Department of Radiation Oncology, University of California, San Francisco, 505 Parnassus Avenue, San Francisco, CA 94143-0226, USA

\* Corresponding author.

E-mail address: [cageta@neurosurg.ucsf.edu](mailto:cageta@neurosurg.ucsf.edu)

tumor suppressor gene play a key role in tumorigenesis in these patients. Neurofibromatosis type 1 is an autosomal dominant genetic disorder caused by mutations of the neurofibromin gene. The clinical manifestations include cutaneous café au lait spots, neurofibromas in any organ system, optic gliomas, and intracranial HGGs.<sup>9</sup> Turcot syndrome, a disease of DNA mismatch repair characterized by adenomatous colorectal polyps and malignant neuroepithelial tumors, has been associated with HGGs in children.<sup>10,11</sup> Other diseases of constitutional mismatch repair deficiency, specifically expression of the MSH6 mismatch repair gene mutation has been linked to HGG development in children.<sup>12</sup> In addition, there have been case reports of GBM occurring in patients with Ollier disease and Maffucci syndrome, both diseases of cartilaginous dysplasia.<sup>13</sup> However, the significance of the occurrence of these malignancies in these syndromes is unknown.

## **PATHOLOGY**

### ***Histopathology***

AAs are highly proliferative mitotically active tumors of glial origin with increased cellularity and cellular atypia. GBMs consist of active poorly differentiated astrocytes with high mitotic activity. These neoplasms are typically heterogeneous with areas of hypervascularity and necrosis. Often the necrotic areas are toward the center of the lesion and surrounded by dense hypervascular tissue. The peripheral zones of both AA and GBM are composed of less dense cellular layers that invade and infiltrate the surrounding brain tissue. Typically this invasion is along white matter tracts, including the anterior and posterior commissures, corpus callosum, fornix, and internal capsule. Infiltrating tumor cells are commonly found many centimeters from the original tumor location.

### ***Molecular Features***

The molecular profiles of pediatric and adult HGGs are distinct.<sup>14</sup> Mutations in the *p53* tumor suppressor gene are characteristic features of pediatric GBMs and are associated with a poor prognosis. In a multi-institutional trial, the Children's Cancer Group (CCG) identified *p53* mutations in 40.5% of pediatric HGGs.<sup>15</sup> This same *p53* mutation is only seen in secondary adult GBMs. Secondary GBM refers to HGGs that have arisen from the progression of lower-grade gliomas. *p53* overexpression in children is associated with a 5-year progression-free survival (PFS) rate of 17% in comparison with a PFS rate of 44% in patients with low *p53* expression.<sup>16,17</sup>

Epidermal growth factor receptor (EGFR),<sup>18</sup> PTEN,<sup>19</sup> and the Ras pathway<sup>20</sup> are activated in most adult GBMs, although these alterations are only present in a subset of pediatric patients. *EGFR* amplification is rare (<10%) in children with GBMs than in adults with GBMs, although positive and elevated EGFR immunoreactivity is seen in 80% of pediatric tumors. The CCG trial reported that 24% of pediatric GBMs and AAs had *PTEN* deletions.<sup>21</sup> Although mutations in *PTEN* are rare in pediatric GBM than in GBM in adults, if present, a poorer prognosis can be expected. LOH at 10q23 is a common abnormality found in 80% of pediatric GBMs.

There are at least 2 molecular subtypes of pediatric GBM.<sup>20</sup> One has activation of the Ras/Akt and MAPK pathways and is associated with a poor clinical prognosis. The other subtype does not have Ras/Akt or MAPK pathway activation and has a much more favorable prognosis. In most adult GBMs, the Ras pathway is activated. In children with GBMs with Ras activation, high expression of CD133, nestin, *dlx2*, and MELK is also seen.

YB1, a protein involved in brain embryogenesis, is upregulated in 72% of pediatric GBMs.<sup>20</sup> This protein is unique to pediatric GBMs and, when localized to the nucleus, is associated with a poor prognosis. When expressed in the cytoplasm of Ras/Akt-negative GBMs, it was associated with a better outcome. A strong positive association between MIB-1 labeling, patient outcome, and histology has also been found. Mean labeling indices were  $19.4 \pm 2.66$  for tumors classified as AA versus  $32.1 \pm 3.08$  for those classified as GBM ( $P = .0024$ ). The 5-year PFS was  $33\% \pm 7\%$  in 43 patients whose tumors had MIB-1 indices of less than 18%,  $22\% \pm 8\%$  in 27 patients whose tumors had indices between 18% and 36%, and  $11\% \pm 6\%$  in 28 patients whose tumors had indices greater than 36% ( $P = .003$ ), reflecting a significant inverse correlation between proliferative indices and PFS.<sup>22</sup>

Pediatric AAs are associated with both loss and gain of DNA copy number. The most common gains are on chromosome 5q (40%) and 1q (30%), whereas the most common losses are chromosomes 22q (50%) and 6q, 9q (40%).<sup>23</sup> Losses on 17p have also been reported. A shorter survival time is associated with a gain on the 1q arm.<sup>23</sup> *PTEN* mutation is rare (8%) in pediatric AA, but if present is associated with poor prognosis.<sup>23</sup> In addition, *p53* mutations are present in 95% of pediatric AAs.<sup>24</sup>

### ***Clinical Features***

As with many brain tumors, the clinical presentation depends on the anatomic location of

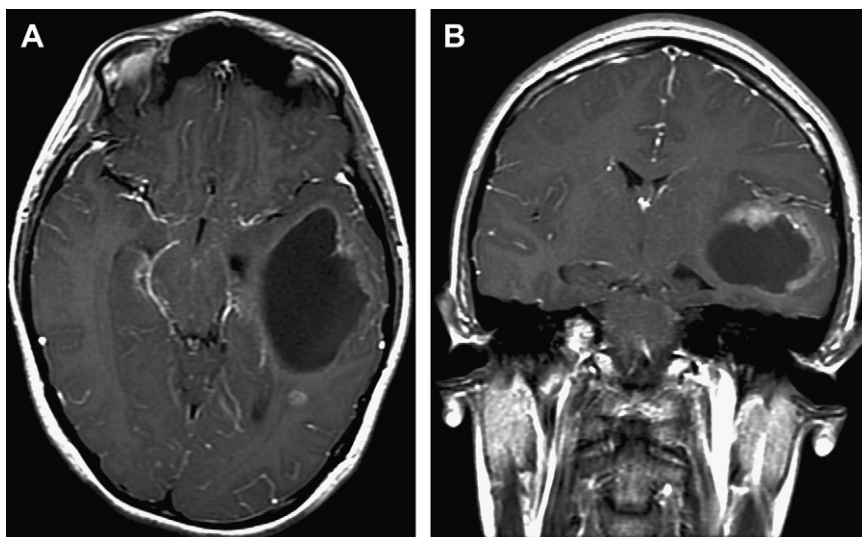
the tumor, associated effects on the surrounding brain, and the age of the patient. Constitutional symptoms such as fatigue, irritability, anorexia, loss of milestones, or failure to thrive can occur but are nonspecific in nature. Signs and symptoms of increased intracranial pressure, such as worsening headaches, nausea, and vomiting, are often seen with intracranial tumors regardless of their diagnosis or grade. Neurologic abnormalities related to tumor location may include hemiparesis; dysphasia; or, less commonly, worsening seizures related to tumor progression. Infants are a special population in whom signs and symptoms may be difficult to interpret. If the cranial sutures are still open, symptoms and signs of increased intracranial pressure may not be present; instead, the head circumference will increase, making room for the growing infiltrating tumor. A rapid increase in head circumference may be the first step in the diagnosis of a brain tumor in infants. The rate of tumor progression is related to tumor grade. Patients with HGGs have a hastening of functional decline and symptoms in comparison with those with lower-grade tumors.<sup>25,26</sup>

### Diagnostic Imaging

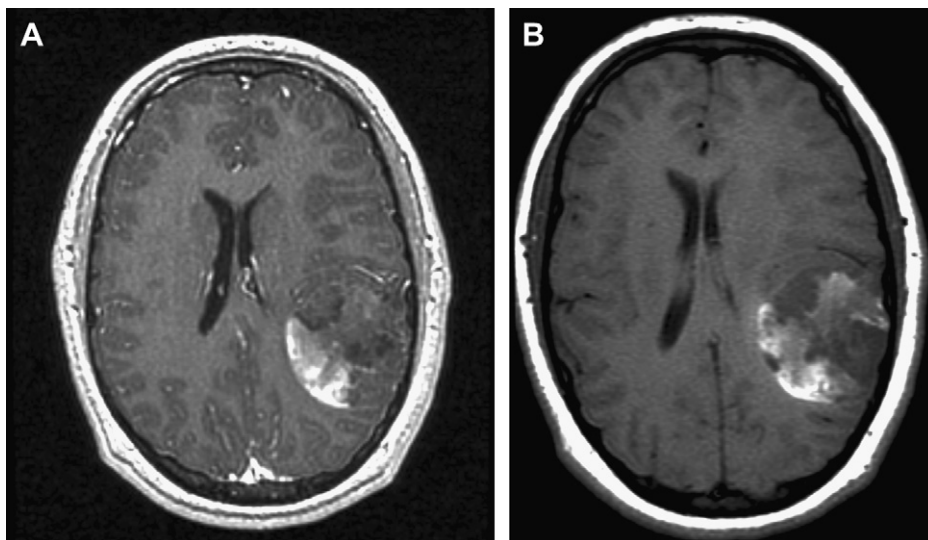
HGGs can be identified on computed tomographic (CT) scans as an irregular isodense or hypodense lesion centered in the white matter. There may be heterogeneous enhancement of the lesion seen on postcontrast sequences. Although CT scans play an important diagnostic role in the early detection of brain tumors in children, magnetic resonance imaging (MRI) is the most sensitive imaging

tool and provides far more anatomic information. At a minimum, the following MRI sequences should be obtained: T1-weighted, precontrast and postcontrast administration, T2-weighted, and fluid-attenuated inversion recovery (FLAIR). Additional specialized magnetic resonance sequences include magnetic resonance spectroscopy (MRS), perfusion, diffusion-weighted imaging, and diffusion tensor imaging (DTI). Functional MRI (fMRI) can provide functional and structural information, which is particularly helpful for surgical planning.<sup>27</sup>

HGGs can have varying imaging features on MRI. They either can have an irregularly enhancing rim surrounding a necrotic core or can be poorly marginated with diffuse infiltration into white matter tracts such as the corpus callosum and anterior and posterior commissures. These tumors are usually solitary but can be multifocal. On pre-contrast T1-weighted sequences, these tumors are isointense or hypointense. After contrast administration, T1-weighted sequences typically show an irregular enhancing rim surrounding a nonenhancing area of central necrosis (**Fig. 1**). Hemorrhage is sometimes present within the tumor (**Fig. 2**). The enhancing portion typically represents mitotically active proliferating tumor cells. T2-weighted and FLAIR sequences usually show a heterogeneous mass with variable signal intensity surrounded by a broad zone of vasogenic edema. Infiltrating malignant tumor cells extend far beyond the area of enhancement. These aggressive tumors have elevated choline level, lactate level, and lipid peaks and decreased *N*-acetyl-aspartate peaks on MRS.<sup>28</sup> Because of the high proliferative index and elevated glucose metabolism



**Fig. 1.** A mainly cystic AA (WHO grade III) in a 6-year-old girl. On the postcontrast axial image (A), the tumor is mainly cystic in appearance. A rim of enhancement is better visualized on the coronal image (B).



**Fig. 2.** A partially hemorrhagic GBM of the left parietal lobe in a 15-year-old boy. The precontrast image (A) shows areas of increased T1-weighted signal intensity consistent with hemorrhage. After gadolinium administration, there are irregular areas of enhancement within the tumor (B).

that characterizes HGGs, PET imaging reveals high fludeoxyglucose uptake in the lesion.

Gliomatosis cerebri is the most diffuse form of HGGs and is identified by tumor infiltration throughout multiple lobes and associated vasogenic edema. Imaging of the neuraxis is indicated when there is a concern for disseminated disease throughout the brain and spinal cord. The differential diagnosis based on imaging includes abscess, demyelination, or other primary malignant brain tumors of childhood, including primitive neuroectodermal tumors, ependymoma, or pleomorphic xanthoastrocytomas.

Following surgery, chemotherapy, and/or radiation therapy, patients should be monitored radiographically for tumor recurrence. Serial MRI with close clinical follow-up is required to detect early evidence of tumor progression.

## TREATMENT

### Surgery

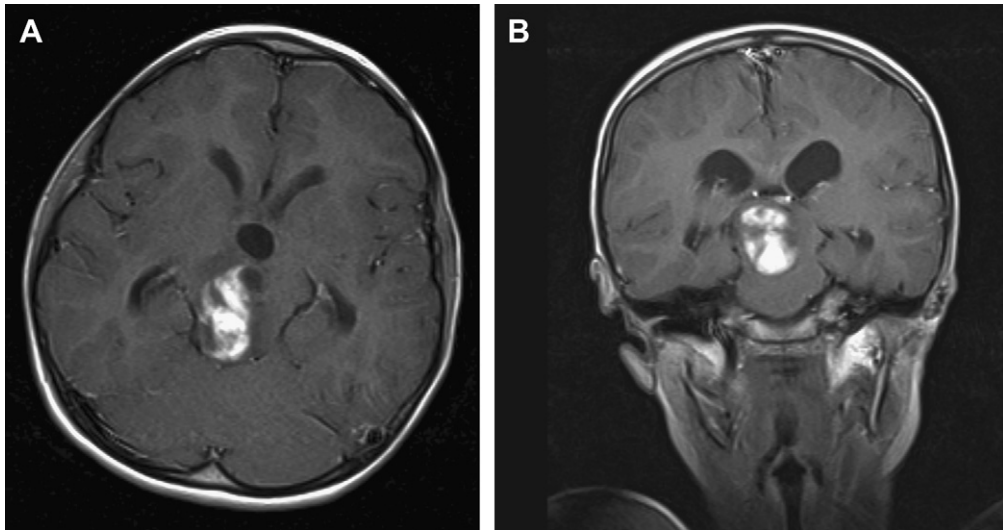
The goals of surgery include obtaining tissue for pathologic diagnosis and achieving a gross total resection (GTR). Depending on tumor location, GTR must be balanced against the development of disabling neurologic deficits. Preoperative MRI sequences such as DTI or fMRI as well as intraoperative image guidance navigation can assist in safely achieving a greater extent of resection while preserving neurologic function for the patient. Because of the infiltrative nature and anatomic location of these tumors, GTR is often not possible. In circumstances in which the tumor is entirely deep in location with involvement of gray

matter nuclei, a limited biopsy may be the only safe option (**Fig. 3**). Once a diagnosis is obtained, adjuvant chemotherapy and/or radiation therapy can be planned.

If GTR cannot be achieved, debulking of the majority of the mass is beneficial. A longer PFS is associated with a greater extent of surgical resection.<sup>29–31</sup> In addition, by removing a portion of the mass, symptoms associated with mass effect can be partially or totally relieved. In the CCG 945 study, children with HGGs who underwent GTRs (defined as >90% resection) had a 5-year PFS rate of 35% ( $\pm 7\%$ ) in comparison with 17% ( $\pm 4\%$ ) in the group that underwent subtotal resection (STR) ( $P = .006$ ).<sup>32</sup> Likewise, patients with AA who underwent GTRs had a 5-year PFS rate of 44% ( $\pm 11\%$ ) in comparison with 22% ( $\pm 6\%$ ) in those who underwent STRs ( $P = .055$ ). Patients with GBM who underwent GTRs had a 5-year PFS rate of 26% ( $\pm 9\%$ ) in comparison with 4% ( $\pm 3\%$ ) in those who underwent STRs ( $P = .046$ ).<sup>32</sup> In this same study, the 5-year event-free survival rate (event defined as relapse or death from any cause) for patients with oligoastrocytomas was  $37.5\% \pm 17\%$ .<sup>33</sup>

### Radiation Therapy

Radiation therapy is the standard of care after surgical resection for children older than 3 years. The neurologic sequelae of radiation therapy include neurocognitive decline, secondary malignancy, endocrinopathy, and vasculopathy, depending on the location of the tumor and the required radiation treatment volume and dose.



**Fig. 3.** A heterogeneous-appearing AA in the upper midbrain and thalamus. Lesion enhancement is observed following gadolinium administration in the axial (A) and coronal (B) images. This lesion was not amenable to GTR, and diagnosis was obtained by stereotactic biopsy.

Therefore, younger children, in particular those younger than 3 years, are often treated with chemotherapy after surgical resection to delay radiation therapy. For those patients older than 3 years, fractionated external beam radiation is the standard of care. Patients are treated with 54 to 60 Gy delivered in daily fractions of 1.8 to 2.0 Gy. Hyperfractionated radiotherapy, in which more than one fraction of radiation is administered daily, typically with a lower dose per fraction, has not proven to improve outcomes nor decrease associated side effects of radiation.<sup>34,35</sup>

### Chemotherapy

Following surgical resection, chemotherapy is started usually in combination with radiation therapy, although it is often continued as maintenance therapy. For children younger than 3 years, chemotherapy can be administered as a primary therapy to delay radiation as long as possible. The effectiveness of adjuvant chemotherapy in addition to radiation therapy after surgical resection of HGGs in children is not well established, and most children with HGGs are treated on a clinical trial. The first randomized trial testing the efficacy of chemotherapy was conducted in the 1980s by the CCG. Children with HGGs were randomized after surgery to receive radiation therapy with or without chemotherapy with prednisone, lomustine, and vincristine. Children who received postradiation chemotherapy had better PFS (46%) than those who did not receive chemotherapy (26%).<sup>36</sup> This benefit was most apparent

in patients with GBM who had at least partial tumor resection. In a subsequent CCG study, patients were randomized to receive 1 of 2 chemotherapy regimens comparing an intensive “8-drugs-in-one-day” regimen with the standard regimen of prednisone, vincristine, and lomustine. No difference in 5-year PFS was seen between these regimens (33% vs 36%).<sup>29</sup> Based on these data, adding adjuvant chemotherapy to radiation seems to provide a small survival benefit.

Since these early studies, chemotherapy has been added to radiation therapy in different schedules, including a “sandwich” protocol (before and after radiation therapy), concomitant administration, and maintenance therapy. Single agents including etoposide, cyclophosphamide, irinotecan, platinum compounds, procarbazine, CCNU and vincristine, and topotecan have been studied in phase 2 trials with marginal effects on overall survival. Because concomitant temozolomide (TMZ) and radiation therapy for adult patients with GBM led to prolonged survival and is now considered the standard of care, several studies have tested the efficacy of this drug in pediatric patients.<sup>37–40</sup> Multiple other studies, including 2 large national Children’s Oncology Group studies, had disappointing outcomes and failed to demonstrate a benefit of TMZ on long-term survival in pediatric patients with HGGs, including brainstem gliomas.<sup>39,41–43</sup> Ongoing trials are evaluating TMZ in combination with additional chemotherapeutic agents such as the PARP inhibitor ABT-888 or in combination with radiation and ABT-888 as upfront treatment of pediatric brainstem glioma.



High-dose myeloablative chemotherapy with autologous hematopoietic stem cell rescue (ASCR) has also been explored, and its role in the treatment of HGG remains unproved. The CCG 9922 study using thiotepa, BCNU, and etoposide followed by ASCR and focal radiation therapy resulted in a 2-year PFS rate of 46% ( $\pm 14\%$ ).<sup>44</sup> This study was closed early after 5 of the 11 treated patients developed significant pulmonary complications. Another study using thiotepa in patients with newly diagnosed HGG showed a 4-year survival rate of 46%.<sup>45</sup> The most appropriate candidates for myeloablative therapy are those with complete or near-complete resection before myeloablative therapy.<sup>46</sup> The use of high-dose chemotherapy with ASCR may contribute to long-term disease control but at the expense of significant morbidity and mortality as a consequence of the regimens themselves. The associated side effects and resultant poor quality of life have led many investigators to question the benefit of high-dose chemotherapy with ASCR despite the potential for better disease control.

At present, a combination of surgery, radiation, and chemotherapy is the standard therapy for children with HGGs who are older than 3 years. The most effective chemotherapy regimen, however, is still under investigation.

## OUTCOME

A diagnosis of HGG, either GBM or AA, carries a poor prognosis. In general, pediatric patients have a more favorable course than adults with the same diagnosis.<sup>47</sup> Histologic characteristics, amenability to surgical resection, and ability to tolerate adjuvant therapies all contribute to a patient's individual survival rate. Patients with grade IV tumors (GBM) have a worse prognosis than those with grade III tumors (AA).<sup>29,48</sup> Similarly, patients who undergo GTR have improved 5-year PFS in comparison with those who receive only STR or biopsy. In addition, patients who are able to tolerate radiation and chemotherapy after resection have an increased survival rate in comparison with those who do not undergo any adjuvant treatment.

Functional outcomes are influenced by location and extent of the tumor. For patients who have large tumors that involve the eloquent brain, preoperative deficits can be profound. Treatment side effects, particularly those associated with radiation therapy, to the developing neuraxis can translate into developmental comorbidities. Neuropsychological delay, endocrinopathies, vasculopathies, and cognitive delay/decline are not uncommon sequelae of radiation therapy.

Although prognosis is generally poor for patients with HGGs, secondary malignancies have been reported after undergoing radiation to the neuraxis and after exposure to chemotherapeutic agents (eg, alkylating agents and etoposide). Because of this, regular monitoring with serial MRI is crucial to follow up tumor progression.

## FUTURE DIRECTIONS

Current studies and trials seek to identify new molecular targets for therapeutic intervention or attempt to uncover new drug combinations to limit treatment side effects while extending life expectancy. Significant progress in the last several years has greatly increased our understanding of the underlying molecular mechanisms that are involved in the tumorigenesis of pediatric HGGs. These findings are now being translated into targeted therapies and are entering early phase 1 clinical trials. For example, the PI3K/Akt/mTOR pathway as well as BRAF<sup>V600E</sup> are promising new targets. An analysis of 74 pediatric HGGs revealed *EGFR* amplification in 4 of 43 pediatric GBMs (11%) and 2 of 11 pediatric AAs (14%). The constitutively active EGFRvIII mutant form was present in 6 of 35 (17%) cases.<sup>49</sup> *PDGFR* amplification is present in approximately 15% of pediatric HGGs, and gene expression pathway analysis revealed that RTK signaling is dysregulated in approximately 25% of pediatric HGGs.<sup>49</sup> These findings amongst others led to the development of a phase 1 trial with the new dual PI3K/mTOR inhibitor XL765 (Sanofi-Aventis) for treatment of recurrent pediatric HGGs. Further, Schiffman and colleagues<sup>50</sup> have reported a frequency of 25% (5/20) of BRAF<sup>V600E</sup> mutations in pediatric HGGs, and a more recent analysis showed a frequency of 10% of BRAF<sup>V600E</sup> mutations in an additional 60 pediatric HGGs.<sup>51</sup> At present, PLX4032, a specific inhibitor of BRAF<sup>V600E</sup>, is being considered for a phase 1 clinical trial for children whose tumors carry this mutation. PLX4032 has already shown remarkable efficacy in patients with refractory metastatic melanoma with a reported response rate of 81% and only mild grade 2 toxicities.<sup>52</sup>

Receptor inhibitors, radiosensitization, and vaccine trials are techniques that are currently under further investigation as potential treatment strategies for these patients. Inhibitors of EGFR or platelet-derived growth factor receptor (PDGFR) are being tested in phase 1/2 trials with and without radiation as well as in combination with conventional chemotherapy.<sup>53</sup> Imatinib (PDGFR inhibitor) has been associated in a phase 1 trial with increased incidence of intracranial hemorrhage, especially in patients with brainstem glioma, which requires further investigation.<sup>54</sup> Results from

a phase 2 trial (HIT-GMB-D) using high-dose methotrexate showed results superior to that in the control groups, and therefore this regimen is being tested as a phase 3 study.<sup>55</sup> Investigators are currently studying the increased effectiveness of chemotherapeutic agents used before radiation therapy as radiosensitizers.<sup>56</sup> Although vaccine trials have been used in adults with HGGs, there are less data for the pediatric population. Dendritic cell-based tumor vaccination trials in children with recurrent malignant brain tumors are underway.<sup>57</sup> Early results have shown that recurrent HGGs respond favorably to vaccination with a 6-month PFS of 42% and an overall survival of 21.2% at a median follow-up of 35.7 months after surgical resection and subsequent vaccination.

Laboratory investigations are setting the stage for further clinical therapies. For example, gefitinib, a GFR tyrosine kinase inhibitor, has been shown in the laboratory to alter EGFR phosphorylation.<sup>58</sup> Gene therapy using toxin-producing viral vector constructs to induce selective killing of rapidly proliferating tumor cells are also currently under investigation. Further analysis of the underlying molecular events leading to pediatric HGG will enhance clinicians' understanding and lead to improved targeted therapies.

## SUMMARY

Pediatric HGGs include AAs, anaplastic oligodendrogliomas, and GBM. Pediatric patients present with a variety of clinical symptoms that vary greatly with age of the patient, making early diagnosis potentially more difficult than that in adults. MRI plays a critical role in the early detection of brain tumors in children, especially when clinical symptoms are nonspecific. Definitive diagnosis of HGG rests on gaining a tissue sample from surgical biopsy or resection. Although diagnosis is the main goal of surgery in these patients, debulking of the mass is critical both for symptomatic relief and to increase survival rates among patients. The standard of care in children includes surgical resection, radiation therapy (for children older than 3 years), and maintenance chemotherapy. Current clinical trials and laboratory studies are investigating new molecular targets, tumor cell sensitization to radiation and chemotherapy, and dendritic cell vaccinations.

## REFERENCES

- Pollack IF. Brain tumors in children. *N Engl J Med* 1994;331:1500.
- Kleihues P, Louis DN, Scheithauer BW, et al. The WHO classification of tumors of the nervous system. *J Neuropathol Exp Neurol* 2002;61:215.
- Tamber MS, Rutka JT. Pediatric supratentorial high-grade gliomas. *Neurosurg Focus* 2003;14:e1.
- CBTRUS. 2009-2010 CBTRUS statistical report: primary brain and central nervous system tumors diagnosed in eighteen states in 2002-2006. Hinsdale (IL): Central Brain Tumor Registry of the United States; 2009.
- Perkins S, Rubin J, Leonard J, et al. Glioblastoma in children: a single-institution experience. *Int J Radiat Oncol Biol Phys* 2011;80:1117.
- Pettorini BL, Park YS, Caldarelli M, et al. Radiation-induced brain tumours after central nervous system irradiation in childhood: a review. *Childs Nerv Syst* 2008;24:793.
- Li FP, Fraumeni JF Jr, Mulvihill JJ, et al. A cancer family syndrome in twenty-four kindreds. *Cancer Res* 1988;48:5358.
- Varley JM, McGown G, Thorncroft M, et al. Germ-line mutations of TP53 in Li-Fraumeni families: an extended study of 39 families. *Cancer Res* 1997;57:3245.
- Jouhilahti E, Peltonen S, Heape A, et al. The pathoetiology of neurofibromatosis 1. *Am J Pathol* 1932;178:2011.
- Turcot J, Despres JP, St Pierre F. Malignant tumors of the central nervous system associated with familial polyposis of the colon: report of two cases. *Dis Colon Rectum* 1959;2:465.
- Lusis E, Travers S, Jost S, et al. Glioblastomas with giant cell and sarcomatous features in patients with Turcot syndrome type 1: a clinicopathological study of 3 cases. *Neurosurgery* 2010;67:811.
- Felsberg J, Thon N, Eigenbrod S, et al. Promoter methylation and expression of MGMT and the DNA mismatch repair genes MLH1, MSH2, MSH6 and PMS2 in paired primary and recurrent glioblastomas. *Int J Cancer* 2011;129:659.
- Ranger A, Szymczak A, Hammond R, et al. Promoter methylation and expression of MGMT and the DNA mismatch repair genes MLH1, MSH2, MSH6 and PMS2 in paired primary and recurrent glioblastomas. *J Neurosurg Pediatr* 2009;4:363.
- Pfister S, Witt O. Pediatric gliomas. Recent results. *Cancer Res* 2009;171:67.
- Pollack IF, Hamilton RL, James CD, et al. Rarity of PTEN deletions and EGFR amplification in malignant gliomas of childhood: results from the Children's Cancer Group 945 cohort. *J Neurosurg* 2006;105:418.
- Pollack IF, Finkelstein SD, Burnham J, et al. Age and TP53 mutation frequency in childhood malignant gliomas: results in a multi-institutional cohort. *Cancer Res* 2001;61:7404.
- Pollack IF, Finkelstein SD, Woods J, et al. Expression of p53 and prognosis in children with malignant gliomas. *N Engl J Med* 2002;346:420.
- Bredel M, Pollack IF, Hamilton RL, et al. Epidermal growth factor receptor expression and gene

- amplification in high-grade non-brainstem gliomas of childhood. *Clin Cancer Res* 1999;5:1786.
19. Nakamura M, Shimada K, Ishida E, et al. Molecular pathogenesis of pediatric astrocytic tumors. *Neuro Oncol* 2007;9:113.
  20. Faury D, Nantel A, Dunn S, et al. Molecular profiling identifies prognostic subgroups of pediatric glioblastoma and shows increased YB-1 expression in tumors. *J Clin Oncol* 2007;25:1196.
  21. Liu W, James CD, Frederick L, et al. PTEN/MMAC1 mutations and EGFR amplification in glioblastomas. *Cancer Res* 1997;57:5254.
  22. Pollack IF, Hamilton RL, Burnham J, et al. Impact of proliferation index on outcome in childhood malignant gliomas: results in a multi-institutional cohort. *Neurosurgery* 2002;50:1238.
  23. Rickert C, Strater R, Kaatsch P, et al. Pediatric high-grade astrocytomas show chromosomal imbalances distinct from adult cases. *Am J Pathol* 2001;158:1525.
  24. Sung T, Miller DH, Hayes RL, et al. Preferential inactivation of the p53 tumor suppressor pathway and lack of EGFR amplification distinguish de novo high grade pediatric astrocytomas from de novo adult astrocytomas. *Brain Pathol* 2000;10:249.
  25. Mehta V, Chapman A, McNeely PD, et al. Latency between symptom onset and diagnosis of pediatric brain tumors: an Eastern Canadian geographic study. *Neurosurgery* 2002;51:365.
  26. Duffner PK. Diagnosis of brain tumors in children. *Expert Rev Neurother* 2007;7:875.
  27. Osborn A, Blaser S, Salzman K, et al. Diagnostic imaging brain. Salt Lake City (UT): Amirsys; 2007.
  28. Steffen-Smith E, Shih J, Hipp S, et al. Proton magnetic resonance spectroscopy predicts survival in children with diffuse intrinsic pontine glioma. *J Neurooncol* 2011;105:365.
  29. Finlay JL, Boyett JM, Yates AJ, et al. Randomized phase III trial in childhood high-grade astrocytoma comparing vincristine, lomustine, and prednisone with the eight-drugs-in-1-day regimen. *Childrens Cancer Group. J Clin Oncol* 1995;13:112.
  30. Heideman RL, Kuttlesch J Jr, Gajjar AJ, et al. Supratentorial malignant gliomas in childhood: a single institution perspective. *Cancer* 1997;80:497.
  31. Wolff JE, Gnekow AK, Kortmann RD, et al. Preradiation chemotherapy for pediatric patients with high-grade glioma. *Cancer* 2002;94:264.
  32. Wisoff JH, Boyett JM, Berger MS, et al. Current neurosurgical management and the impact of the extent of resection in the treatment of malignant gliomas of childhood: a report of the Children's Cancer Group trial no. CCG-945. *J Neurosurg* 1998;89:52.
  33. Hyder D, Sung L, Pollack I, et al. Anaplastic mixed gliomas and anaplastic oligodendroglioma in children: results from the CCG 945 experience. *J Neurooncol* 2007;83:1.
  34. Fulton DS, Urtasun RC, Scott-Brown I, et al. Increasing radiation dose intensity using hyperfractionation in patients with malignant glioma. Final report of a prospective phase I-II dose response study. *J Neurooncol* 1992;14:63.
  35. Packer RJ, Boyett JM, Zimmerman RA, et al. Hyperfractionated radiation therapy (72 Gy) for children with brain stem gliomas. A Childrens Cancer Group Phase I/II Trial. *Cancer* 1993;72:1414.
  36. Spoto R, Ertel IJ, Jenkin RD, et al. The effectiveness of chemotherapy for treatment of high grade astrocytoma in children: results of a randomized trial. A report from the Childrens Cancer Study Group. *J Neurooncol* 1989;7:165.
  37. Stupp R, Dietrich PY, Ostermann Kraljevic S, et al. Promising survival for patients with newly diagnosed glioblastoma multiforme treated with concomitant radiation plus temozolomide followed by adjuvant temozolomide. *J Clin Oncol* 2002;20:1375.
  38. Cohen BH, Zeltzer PM, Boyett JM, et al. Prognostic factors and treatment results for supratentorial primitive neuroectodermal tumors in children using radiation and chemotherapy: a Childrens Cancer Group randomized trial. *J Clin Oncol* 1995;13:1687.
  39. Cohen K, Pollack I, Zhou T, et al. Temozolomide in the treatment of high-grade gliomas in children: a report from the Children's Oncology Group. *Neuro Oncol* 2011;13:317.
  40. Cohen K, Heideman R, Zhou T, et al. Temozolomide in the treatment of children with newly diagnosed diffuse intrinsic pontine gliomas. *Neuro Oncol* 2011;13:410.
  41. Nicholson HS, Kretschmar CS, Krailo M, et al. Phase 2 study of temozolomide in children and adolescents with recurrent central nervous system tumors: a report from the Children's Oncology Group. *Cancer* 2007;110:1542.
  42. Lashford LS, Thiesse P, Jouvet A, et al. Temozolomide in malignant gliomas of childhood: a United Kingdom Children's Cancer Study Group and French Society for Pediatric Oncology Intergroup Study. *J Clin Oncol* 2002;20:4684.
  43. Estlin EJ, Lashford L, Ablett S, et al. Phase I study of temozolomide in paediatric patients with advanced cancer. United Kingdom Children's Cancer Study Group. *Br J Cancer* 1998;78:652.
  44. Grovas AC, Boyett JM, Lindsley K, et al. Regimen-related toxicity of myeloablative chemotherapy with BCNU, thiopeta, and etoposide followed by autologous stem cell rescue for children with newly diagnosed glioblastoma multiforme: report from the Children's Cancer Group. *Med Pediatr Oncol* 1999;33:83.
  45. Massimino M, Gandola L, Luksch R, et al. Sequential chemotherapy, high-dose thiopeta, circulating



- progenitor cell rescue, and radiotherapy for childhood high-grade glioma. *Neuro Oncol* 2005;7:41.
46. Marachelian A, Butturini A, Finlay J. Myeloablative chemotherapy with autologous hematopoietic progenitor cell rescue for childhood central nervous system tumors. *Bone Marrow Transplant* 2008; 41:167.
47. Wolff J, Driever P, Erdlenbruch B, et al. Intensive chemotherapy improves survival in pediatric high-grade glioma after gross total resection: results of the HIT-GBM-C protocol. *Cancer* 2010;116:705.
48. Pollack I. Multidisciplinary management of childhood brain tumors: a review of outcomes, recent advances, and challenges. *J Neurosurg Pediatr* 2011;8:135.
49. Bax D, Gaspar N, Little S, et al. EGFRvIII deletion mutations in pediatric high-grade glioma and response to targeted therapy in pediatric glioma cell lines. *Clin Cancer Res* 2009;15:5753.
50. Schiffman J, Hodgson J, VandenBerg S, et al. Oncogenic BRAF mutation with CDKN2A inactivation is characteristic of a subset of pediatric malignant astrocytomas. *Cancer Res* 2010;70:512.
51. Nicolaidis T, Li H, Solomon D, et al. Targeted therapy for BRAFV600E malignant astrocytoma. *Clin Cancer Res* 2011;17:7595.
52. Flaherty K, Puzanov I, Kim K, et al. Inhibition of mutated, activated BRAF in metastatic melanoma. *N Engl J Med* 2010;363:809.
53. Gadji M, Crous A, Fortin D, et al. EGF receptor inhibitors in the treatment of glioblastoma multiform: old clinical allies and newly emerging therapeutic concepts. *Eur J Pharmacol* 2009;625:23.
54. Pollack IF, Jakacki RI, Blaney SM, et al. Phase I trial of imatinib in children with newly diagnosed brainstem and recurrent malignant gliomas: a Pediatric Brain Tumor Consortium report. *Neuro Oncol* 2007;9:145.
55. Wolff J, Kortmann R, Wolff B, et al. High dose methotrexate for pediatric high grade glioma: results of the HIT-GBM-D pilot study. *J Neurooncol* 2011;102:433.
56. van Vuurden D, Hulleman E, Meijer O, et al. PARP inhibition sensitizes childhood high grade glioma, medulloblastoma and ependymoma to radiation. *Oncotarget* 2011;2:984.
57. Ardon H, De Vleeschouwer S, Van Calenbergh F, et al. Adjuvant dendritic cell-based tumour vaccination for children with malignant brain tumours. *Pediatr Blood Cancer* 2010;54:519.
58. Hatziaapiou K, Braoudaki M, Karpusas M, et al. Evaluation of antitumor activity of gefitinib in pediatric glioblastoma and neuroblastoma cells. *Clin Lab* 2011;57:781.